

The Distinguished Electrocardiographic Patterns that Indicate a Severe Left Anterior Descending Coronary Artery Disease

Filipa Alexandra Carvalho Amorim*

Cardiac and Respiratory Physiologist, Unilabs Portugal, Porto, Portugal

***Corresponding Author:** Filipa Alexandra Carvalho Amorim, Cardiac and Respiratory Physiologist, Unilabs Portugal, Porto, Portugal.

Received: March 02, 2019; **Published:** April 22, 2019

Abstract

Coronary artery disease (CAD) is an epidemic phenomenon worldwide, so it's important for physicians not only to prevent it, but also to be aware of all its clinical presentations mainly during the acute period, in order to avoid a massive acute myocardial infarction (AMI) and to provide appropriate treatment. The presence of a severe left anterior descending (LAD) coronary artery disease is serious and may lead to an AMI, decrease in heart function and even death. Clinical entities such as the Wellens' syndrome or the De Winter T waves are representative of a severe LAD coronary artery disease, so it's important to recognize them immediately, to provide adequate treatment.

Keywords: *Coronary Artery Disease; Myocardial Infarction; Acute Coronary Syndrome; Electrocardiography; De Winter T Wave; Wellens's Syndrome*

Abbreviations

CAD: Coronary Artery Disease; AMI: Acute Myocardial Infarction; ECG: 12 Lead Electrocardiogram; ACS: Acute Coronary Syndrome; STEMI: ST-Elevation Myocardial Infarction; PCI: Percutaneous Coronary Intervention; ESC: European Society of Cardiology; AHA: American Heart Association; LAD: Left Anterior Descending; LBBB: Left Bundle Branch Block

Coronary artery disease

Coronary Artery Disease (CAD) is the main cause of mortality worldwide [1,2], being currently responsible for 12,8% of deaths worldwide [1]. It's estimated that in the United States of America more than 900000 individuals will suffer from an acute myocardial infarction (AMI) or die of CAD only this year [2].

The resting 12 lead electrocardiogram (ECG) is the first and most widely non-invasive diagnostic exam to perform in patients with suspected acute coronary syndrome (ACS) [1,3,4]. This exam should be performed at the first contact with the emergency medical team or at the arrival at the emergency department [1].

ECG criteria for a ST- Elevation Myocardial Infarction (STEMI) [1,5]:

New ST-Segment elevation at the J point in at least two contiguous derivations with:

- $\geq 1,5$ mm for women;
- ≥ 2 mm for men over 40 years;
- $\geq 2,5$ mm for men under 40 years;
- ≥ 1 mm in limb derivations;
- $\geq 0,5$ mm in V7-V9 derivations.

However, the ECG may not have STEMI criteria in about 30% of cases of ACS [1,3]. Other hallmarks of cardiac ischemia include ST-segment depression, T wave alterations [3] and elevated cardiac enzymes.

When a patient is diagnosed with STEMI, the recommended treatment for coronary occlusion is percutaneous coronary intervention (PCI) by the European Society of Cardiology (ESC) [6] and the American Heart Association (AHA) [7].

However, there exist some clinical entities that are considered by several authors like STEMI equivalents, such as: newly developed left bundle branch block (LBBB), old LBBB with the presence of Sgarbossa criteria, ST-segment depression in at least 6 derivations and ST-segment elevation in AVR due to left main coronary artery occlusion, Wellens’ syndrome and the De Winter T waves [1,5]. The majority of these conditions were mentioned in the 2017 ESC STEMI guidelines [6], but the De Winter T waves and the Wellens’ syndrome weren’t mentioned in the list of conditions who needed immediate PCI [1,6].

The occlusion or a critical stenosis of the left anterior descending (LAD) coronary artery, provokes an extensive anterior myocardial infarction which is commonly detected in the ECG by ST-segment elevation in the anterior derivations (V1-V4), which causes a serious depression of cardiac function and even death due to the extensive area affected. These patients require immediate PCI in order to prevent a massive infarct [4].

Wellens’ syndrome

Wellens’ syndrome was described in 1982 by Zwann and Wellens, and it’s a high-risk presentation of signs and symptoms and an ECG characteristic pattern in patients with a critical stenosis of the proximal LAD coronary artery [3,8-11].

Criteria for Wellens’ syndrome [3,8-11]:
<ul style="list-style-type: none"> • History of angina; • Minimal or no elevation of cardiac enzymes; • Minimal or no ST-segment elevation (<1mm); • No pathological precordial Q waves in the ECG; • Biphasic T waves in derivations V2 and V3 (type 1) or deep, symmetrical and inverted T waves in derivations V2 and V3, and occasionally V1, V4, V5 and V6 (type 2) - (Figure 1).

The ECG alterations characteristic of Wellens’ syndrome should be recorded in a pain free period [11].

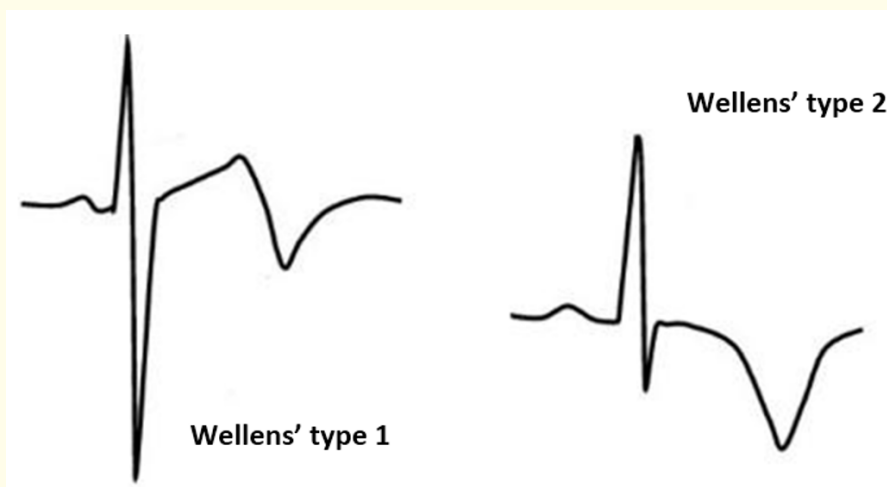


Figure 1: Electrocardiographic pattern representative of Wellens’ pattern type 1 and type 2.

Wellens' syndrome is an indicator of anterior myocardial ischaemia and could be overlooked due to the absence of ST-segment elevation [10]. However, this pattern has a positive predictive value of approximately 86% [10] and these patients usually develop an extensive anterior infarction within days [3,10].

This syndrome is not described as a STEMI equivalent, and guidelines recommend a conservative treatment of these patients, which leads to an inevitable progression to an extensive anterior infarction and a potential death [3].

So, it's important to recognize this syndrome and change the approach in these patients [10,11]. Once Wellens' syndrome has been diagnosed, these patients should do an emergency coronary angiography [10,11] and do a revascularization via PCI [11]. This urgent treatment instead of the conservative pharmacologic approach in these patients it's important to prevent an acute anterior myocardial infarction [9,11].

The De Winter T waves

The De Winter ECG pattern was reported in 2008 by De Winter, *et al.* [12] and it's considered an anterior STEMI equivalent, meaning an acute LAD coronary artery occlusion [1,5,8,13]. This ECG pattern is characterized by a 1 - 3 mm upsloping ST-segment depression at the J point with tall and positive T-waves in precordial leads (V1-V6) (Figure 2) in most patients it's also present a ST-segment elevation at the J point of 0,5 - 1 mm in AVR, mild ST-segment depression in the inferior wall derivations and normal or slightly elongated QRS intervals [1,3,4,8,12-16].

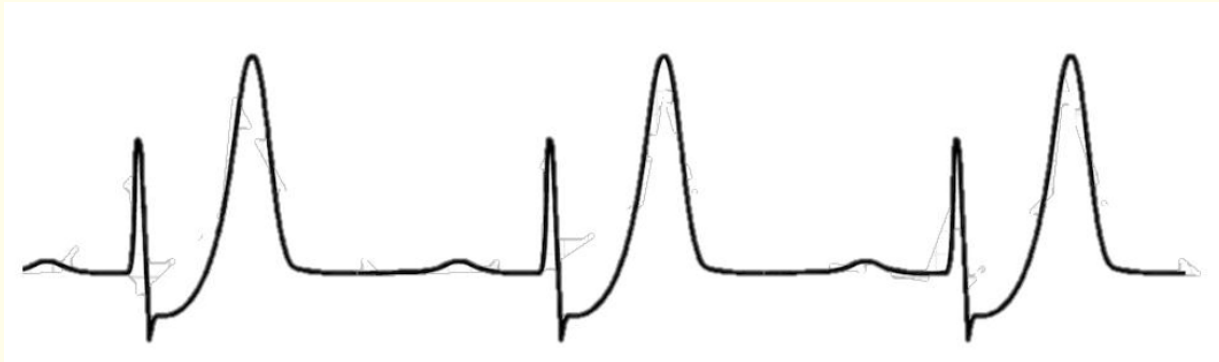

Figure 2: Electrocardiographic pattern representative of the De Winter T waves.

This ECG pattern is found in 2% of anterior myocardial infarctions [5,13,15,17] and has a positive predictive value of 95,2% - 100% when found on ECG, which supports its clinical diagnosis [3,8,13]. Patients with the De Winter ECG pattern are generally younger, male and have a high incidence of hypercholesterolemia, compared with patients with LAD coronary artery occlusion that have a classic anterior STEMI on the ECG [4,13,17,18].

The De Winter T waves may be confused with hyperacute T waves, that can occur due to hyperkalaemia and also as a signal of early ischaemia [4,8,12,16]. However, this pattern doesn't change over time, being persistent, which helps physicians to distinguish it from hyperacute T waves [4,8,12,16].

The aetiology for this pattern is still inconclusive, but several theories have been suggested, such as the presence of an anatomical variant of Purkinje fibres that causes an intraventricular conduction delay and provokes this pattern in cases of occlusion of LAD coronary artery [3,5,17].

This pattern was recognized as an anterior STEMI equivalent in 2010 by Rokos, *et al.* [17,18], however it's often not treated as a STEMI equivalent [15]. The 2017 ESC STEMI guidelines [6] haven't included the De Winter T waves in the immediate invasive strategy list, but

also 2014 AHA Non-STEMI guidelines [19] and the 2013 AHA STEMI [7] guidelines doesn't mention the De Winter ECG pattern, which can explain the fact that this pattern sometimes isn't treated as a STEMI equivalent.

Discussion

The ECG is considered the fastest and main non-invasive exam to diagnose an ACS, so all the physicians should be familiarized with the possible ECG abnormal findings that are present in an ACS [1,3,14,15,17]. Missing the De Winter ECG pattern or the Wellens' syndrome leads to the undertreatment of patients with a STEMI or a potential STEMI, which has adverse effects on morbidity and mortality [8]. Despite the fact that the De Winter ECG pattern or the Wellens' syndrome not meet strictly the criteria for urgent/primary PCI activation, it's recommended by several authors [3-5,10,11,13] to activate this resources in order to allow a timely reperfusion of LAD coronary artery and therefore diminish the myocardial damage and improve clinical outcomes for these patients [4,5,13].

Conclusion

To conclude as such, it's important not only to prevent the risk factors to CAD but also that all physicians, cardiac physiologists and nurses to be well informed about these important ECG particularities in order to provide a better treatment for these patients.

Bibliography

1. Canakci ME., *et al.* "Evaluation of acute anterior myocardial infarction cases with de-Winter T waves by coronary angiography images". *Turkish Journal of Emergency Medicine* 1 (2018).
2. Amit V and Khera SK. "Genetics of coronary artery disease: discovery, biology and clinical translation". *Nature Reviews Genetics* 18.6 (2017): 331-344.
3. Qayyum H., *et al.* "Recognising the de Winter ECG pattern A time critical electrocardiographic diagnosis in the Emergency Department". *Journal of Electrocardiology* 51.3 (2018): 392-395.
4. Yang W., *et al.* "The de Winter electrocardiographic pattern of proximal left anterior descending occlusion". *American Journal of Emergency Medicine* 35.6 (2017): 937.e1-937.e3.
5. Adams R., *et al.* "Prevalence of junctional ST-depression with tall symmetrical T-waves in a pre-hospital field triage system for STEMI patients". *Journal of Electrocardiology* 52 (2019): 1-5.
6. Jeger R., *et al.* "2017 ESC Guidelines for the management of acute myocardial infarction in patients presenting with ST-segment elevation". *European Heart Journal* 39.2 (2017): 119-177.
7. Jessup M., *et al.* "ACCF/AHA Practice Guideline 2013 ACCF/AHA Guideline for the Management of Heart Failure A Report of the American College of Cardiology Foundation/American Heart Association Task Force on Practice Guidelines". *Circulation* 128 (2013): 240-327.
8. Carrington M., *et al.* "De Winter pattern: a forgotten pattern of acute LAD artery occlusion". *BMJ Case Reports* 1 (2018): bcr-2018-226413.
9. Ramires TG., *et al.* "Wellens' syndrome: a pattern to remember". *BMJ Case Reports* (2018): bcr-2018-224582.
10. Yu-Heng C and Raymond YL. "Type B Wellens' Syndrome: Eletrocardiogram patterns that clinicians should be aware of". *Tzu Chi Medical Journal* 29.2 (2017): 65-71.
11. Lan X., *et al.* "Wellens' Syndrome with a proximal left anterior descending artery occlusion". *Clinical Case Reports* 4.6 (2016): 558-560.
12. de Winter RJ., *et al.* "A New ECG Sign of Proximal LAD Occlusion". *New England Journal of Medicine* 359.19 (2008): 2071-2073.

13. Goktas MU., *et al.* "A Novel Electrocardiographic Sign of an ST-Segment Elevation Myocardial Infarction-Equivalent: De Winter Syndrome". *Cardiology Research* 8.4 (2017): 165-168.
14. Zhao YT., *et al.* "de winters ECG changes and anterior myocardial infarction". *QJM: An International Journal of Medicine* 109.4 (2016): 269-271.
15. De Winter RW., *et al.* "Precordial junctional ST-segment depression with tall symmetric T-waves signifying proximal LAD occlusion, case reports of STEMI equivalence". *Journal of Electrocardiology* 49.1 (2016): 76-80.
16. Verouden NJ., *et al.* "Persistent precordial 'hyperacute' T-waves signify proximal left anterior descending artery occlusion". *Heart* 95.20 (2009): 1701-1706.
17. Kailash Kumar Goyal., *et al.* "De Winter sign: A Masquerading electrocardiogram in ST-elevation myocardial infarction". *Heart India* 5.1 (2017): 48-50.
18. Rokos IC., *et al.* "Appropriate Cardiac Cath Lab activation: Optimizing electrocardiogram interpretation and clinical decision-making for acute ST-elevation myocardial infarction". *American Heart Journal* 160.6 (2010): 995-1003.e8.
19. Brindis RG., *et al.* "2014 AHA/ACC Guideline for the Management of Patients With Non- ST-Elevation Acute Coronary Syndromes". *Journal of the American College of Cardiology* 64.24 (2014): e139-e228.

Volume 6 Issue 5 May 2019

©All rights reserved by Filipa Alexandra Carvalho Amorim.