

## When Right-Atrial Floating Thrombus with Massive Pulmonary Embolism Reveal a Behçet Disease: Rare Case Report

**Fatima Zohra Radi\*, Naoual Doghmi, El Hattab Fatimazahra, Hara Loubna and Mohamed Cherti**

*Cardiology B Department, Mohamed V University, IBN ROCHD, Rabat, Morocco*

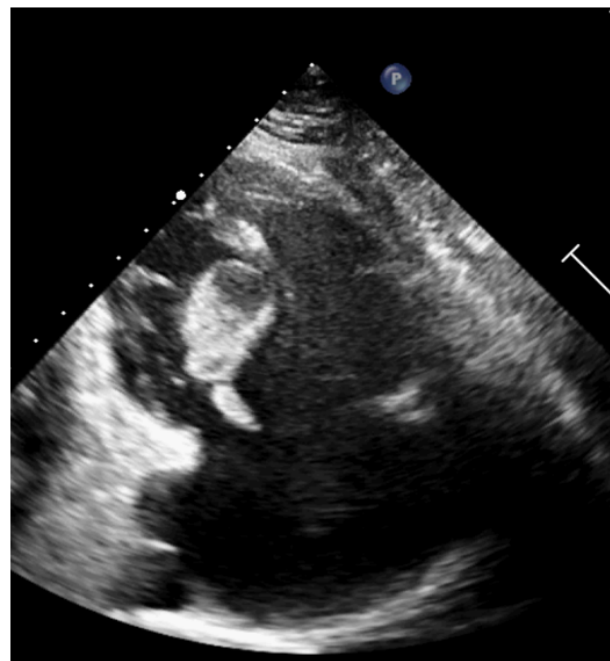
**\*Corresponding Author:** Fatima Zohra Radi, Cardiology B Department, Mohamed V University, IBN ROCHD, Rabat, Morocco.

**Received:** November 25, 2019; **Published:** January 24, 2020

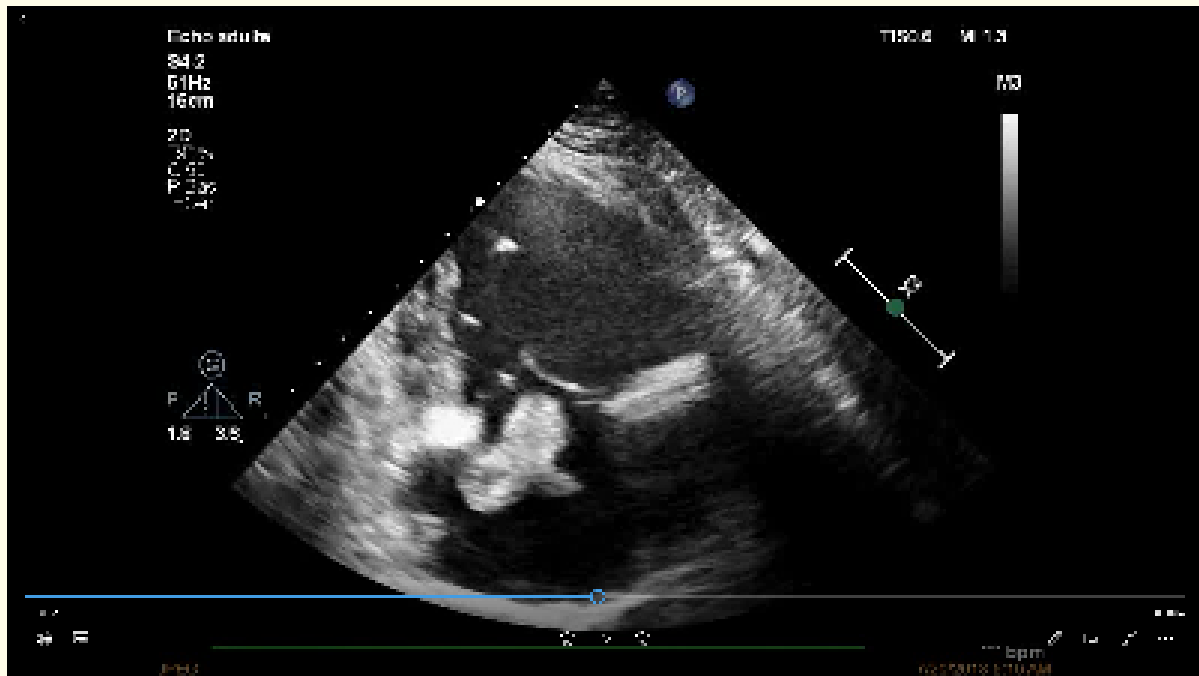
Behçet disease (BD) is a systemic inflammatory disorder. Cardiac complications in BD are rare. The appropriate treatment for of mobile right heart thrombus with pulmonary embolism is controversial and depends on the particular clinical situation.

In July 2018, a 35-year-old patient was transferred for sub-acute dyspnea. The patient reports a history of recurrent oral ulcers and genital ulcers. There was no history of any other systemic manifestations. Systemic examination found tachycardia and hypoxemia.

The echocardiogram demonstrate dilatation of the right cavities and right-atrial floating thrombus (Figure and videos).



**Figure 1:** Figure: Parasternal long axis view centered on the right cavities showed a thrombus that cross the tricuspid valve.



**Video:** Transthoracic echocardiography; parasternal long axis view centered on the right-sided cardiac chambers showing right-atrial floating thrombus which cross the tricuspid valve.

CT angiography of the chest: massive bilateral proximal pulmonary embolism.

Thrombolysis was discussed, but given the hemodynamic stability and the huge thrombus, a surgical thrombectomy with exploration of the right chambers and the pulmonary arteries was urgently indicated.

The presence of recurrent oral ulcers and genital ulcers with this thrombosis represent four points required for the diagnosis of BD According to The International Criteria for Behçet disease (ICBD). In addition, Right heart thrombus in the absence of structural heart disease, atrial fibrillation, or catheter located in the heart is rare.

However, Mass in the right-sided cardiac chambers, even in the absence of the characteristic clinical features of the condition, the diagnosis of BD might still be considered.

Right atrial thrombus treatment consists of medical management including anticoagulation, surgical embolectomy, treatment should be individualized according to the extent of the intracardiac thrombus, the likelihood of pre-existing pulmonary embolism, the patient's cardiopulmonary reserve, co-morbid conditions and local expertise with treatment modalities.

## Conclusion

Vascular involvement is the leading cause of death in BD. thrombi in the right heart cavities should suggest a Behçet's disease despite the absence of specific Criteria.

**Human/Animal Rights**

This article does not contain any studies with human or animal subjects performed by any of the authors.

**Ethics and Consent to Participate Section**

Not applicable.

**Consent to Publish**

Written consent was obtained from the patient for publication of this case with images.

**Competing Interests**

The author(s): Radi Fatima Zohra, El Hattab Fatimazahra, Hara Loubna, Nawal Doghmi and Mohammed Cherty, declare that they have no competing interests.

**Authors Contribution**

Radi Fatima Zohra and Naoual Doghmi have participated equitably in this work.

**Volume 7 Issue 2 February 2020**

**©All rights reserved by Fatima Zohra Radi., et al.**