

Proposed Dr Sachin's Criteria for an Adnexal Torsion Management

Sachin Vijay Naiknaware*

Consultant Gynaecology Endoscopic Surgeon, Breach Candy Hospital, Mumbai, India

***Corresponding Author:** Sachin Vijay Naiknaware, Consultant Gynaecology Endoscopic Surgeon, Breach Candy Hospital, Mumbai, India.

Received: December 09, 2019; **Published:** January 07, 2020

Abstract

Adnexal torsion is 5th most common gynaecological emergency occurring in about 2 - 15% of reproductive age group women, wherein both ovary and fallopian tube twist along the vascular pedicle which causes obstruction to venous outflow and arterial inflow. Clinical presentation of adnexal torsion is highly variable and physical examination is often inconclusive. Early diagnosis increases the chances of saving the ovary and preventing life threatening complications such as thrombophlebitis and peritonitis, associated causes of torsion includes ovarian cyst may it be a follicular cyst or benign dermoid or corpus luteum cyst. Other causes include PCOD, abnormally long utero-ovarian ligament and 10 - 20% cases it is seen in pregnant women.

Various treatment protocols are followed worldwide for the management such as adnexal detorsion alone, detorsion plus ovarian cystectomy in the same sitting or at the interval of 2-3 weeks, Salpingo-oophorectomy, Oophoro-pxy and utero-ovarian ligament plication. But no universally accepted criteria is there recurrence rate. so we are unable to follow these patients objectively for response to treatment, best treatment option and recurrence rate so this criteria will serve the purpose of guiding stones in the management of adnexal torsion. More studies are also needed and this criteria needs to be followed by minimal invasive surgeons worldwide to make it a more acceptable comparable.

Keywords: *Adnexal Torsion; PCOD; Oophoro-pxy*

Introduction

Ovarian torsion occurs when ovarian mass twists on its vascular pedicle. Torsion of ovary is rare but an emergency condition occurring in about 2 - 15% of patients and diagnosing it can be a challenge in an emergency.

Definition

Ovarian torsion can be complex or partial rotation of adnexal structure holding the ovary causing schema in ovary. To better understand pathology we need to have look at adnexal structure at first adult size ovary measures about 3 x 2 x 1 cm and weighs about 3 - 8 gms. Normally in nulliparous it lies in ovarian fossa on lateral pelvic wall. At both ends ovary is attached by ligaments at the tubal pole it is attached by infundibulo-pelvic ligaments which contains the ovarian vessels and at uterine end it is attached by utero-ovarian ligaments.

Torsion most commonly involve both fallopian tube and ovary and isolated torsion is a rare entity occurring in around 1 in 1.5 million women [1]. Torsion is most common in reproductive age group women and during pregnancy and is less common in premenarche and postmenopausal women. Twisting of ovarian pedicle initially obstructs venous flow causing engorgement and ovarian oedema-this engorgement progresses until flow is compromised causing ischemia or infection.

Causes

Ovarian torsion is likely to occur when there is some problem with ovary as in ovarian cyst causing enlargement, pregnancy, hormonal medication use for ovulation induction and sometimes normal ovaries can twist in children's, it can be either intermittent torsion.

on-detorsion causing intermittent pain or complete torsion causing unilateral sudden lower abdominal pain. It is been found that more than 80% of patients with ovarian torsion has ovarian mass more than 5 cm in size and enlarged ovaries. Due to ovarian induction or multi-follicular growth.

Are more amenable to torsion [3]. Also it is been found that benign tumours are more likely to twist than the malignant one.

Torsion due to ovarian cyst is more commonly found in reproductive age group women while more than 50% of premenarchal girls have normal ovaries with torsion at presentation [2].

Of all cases of ovarian torsion 10 - 20% of ovarian torsion cases occurs in pregnancy and most of the cases found at around 10 - 17 weeks of gestation [4].

Clinical presentation

1. Sudden onset of pelvic or abdominal pain which may be localised to lower abdomen.
2. Nausea, vomiting.
3. Low grade fever and tachycardia and on abdominal examination it may reveal generalised abdominal tenderness and localised guarding.

Diagnosis

1. History taking.
2. Clinical examination including per abdominal and vaginal examination.
3. Ultrasound scan including colour doppler.
4. CT scan.
5. MRI scan helpful in pregnancy.
6. Laparoscopy.

Differential diagnosis

1. Pelvic inflammatory disease in which pain is non migratory and on examination there is bilateral fornacial tenderness and usually there is no nausea or vomiting.
2. Appendicitis pain which is usually is migratory pain in initial stages occurring in women less than 40 years of age associated with nausea and vomiting, leukocytosis and localised tenderness in right iliac fossa.
3. Renal colic pain may mimic torsion pain but colic pain is severe intermittent pain and sharp in nature associated with nausea and vomiting.
4. Ovarian cyst or OHSS can also present in a similar way [5].

On colour doppler there can be decreased or absent doppler flow in torsed vessels which gives rise to "whirlpool sign" which is highly sensitive for ovarian torsion [6].

Management of ovarian torsion is same in pregnant patients and laparoscopic surgery is found to be safe in pregnant women [9].

Many observational studies found that detorsion is associated with preserved ovarian function [10] in cases where ovary is black and necroses salpingo-oophorectomy can be performed.

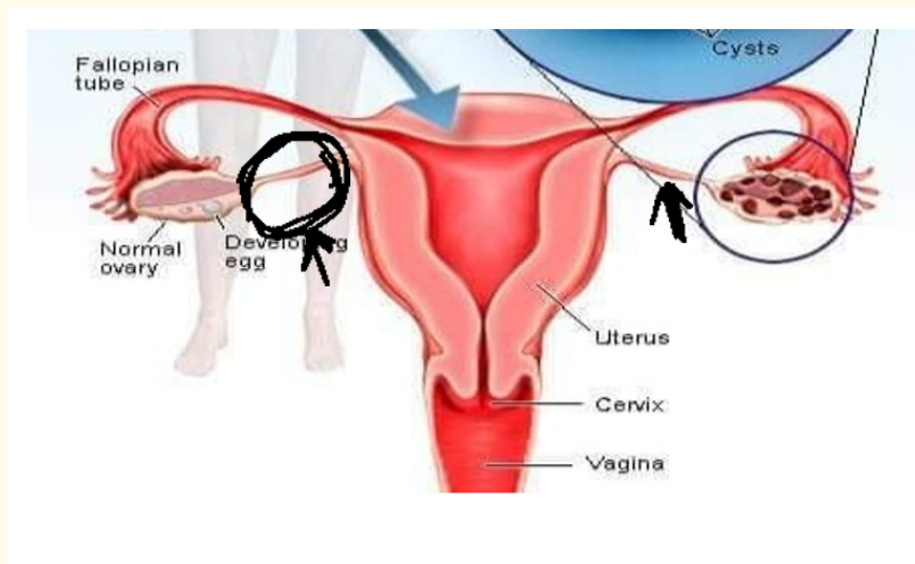
As there is no uniform criteria about the management of adnexal torsion as what to do, whether to do only detorsion, to do oophorectomy or not, to do ligament plication or not and which treatment modality to be used in premenarcheal girl? To answer all these questions a management criteria has been proposed to objectively form the guidelines that can be considered while operating on adnexal torsion cases.

Proposed Dr Sachin's criteria for adnexal torsion management

1. If torsion + ovarian cyst \geq 5 cm do ovarian cystectomy.
2. If utero-ovarian ligament \geq 5 cm do ligament plication.
3. Premenarche torsion or in recurrent torsion use "hot dog in bun" technique.
4. If PCOD + torsion do PCOD drilling + ligament plication + ovarian suppression for 6months.

How to measure utero-ovarian length objectively

Bipolar forceps and bowel graspers are two most commonly used instruments by laparoscopic surgeons. Using this instruments jaw and by applying methylene blue to the tip of these instruments length can be easily measured. Distance between the bissingner probe is 2 cm and between the jaws of bowel grasper its 3 cm.



As at present there is no objective criteria and no clear cut guideline this can help a laparoscopic surgeon to standardize the management protocol and to compare the results and also long term follow up and large scale studies are needed with this criteria to make it widespread used tool for the management of an adnexal torsion in the near future.

Conclusion

These criteria will serve as a guiding stone in the management of adnexal torsion and it will help in standardizing the treatment protocol and it will make easier for result compares on worldwide.

Bibliography

1. Mc Williams GD., *et al.* "Gynaecologic emergencies". *Surgical Clinics of North America* 88.2 (2008): 265-283.
2. Bar-On S., *et al.* "Emergency laparoscopy for suspected ovarian torsion: Are we too hasty to operate?" *Fertility and Sterility* 93 (2010): 2012-2015.
3. Gorkemli H., *et al.* "Adnexal torsion after gonadotrophin ovulation induction for IVF or ICSI and its conservative treatment". *Archives of Gynecology and Obstetrics* 267 (2002): 4-6.
4. Hour D and Abbott JT. "Ovarian torsion: A fifteen- year review". *Annals of Emergency Medicine* 38 (2001): 156-159.
5. Argenta PA., *et al.* "Torsion of the uterine adnexa Pathologic correlation and current management trends". *Journal of Reproductive Medicine* 45 (2000): 831-836.
6. Valsky DV., *et al.* "Added value of the gray scale Whirlpool sign in the diagnosis of adnexal torsion". *Ultrasound in Obstetrics and Gynecology* 36 (2010): 630-634.
7. Johnson TR and Woodruff JD. "Surgical emergencies of the uterine adnexa during pregnancies". *International Journal of Gynecology and Obstetrics* 24 (1986): 331-335.
8. Germain M., *et al.* "Management of intermittent ovarian torsion by laparoscopic oophoropexy". *Obstetrics and Gynecology* 88 (1996): 715-717.
9. Mathevet P., *et al.* "Laparoscopic management of adnexal masses in pregnancy: A case series". *European Journal of Obstetrics and Gynecology and Reproductive Biology* 108 (2003): 217-222.
10. Harkins G. "Ovarian torsion treated with untwisting: second look 36 hours after untwisting". *Journal of Minimally Invasive Gynecology* 14 (2007): 270.

Volume 9 Issue 2 February 2020

© All rights reserved by Sachin Vijay Naiknaware.