

Rectal Prolapse Following Posterior Sagittal Anorectoplasty for Low-Type Anorectal Malformations. A Case Report

Nadji Boughaba*

Pediatric Surgery, Algeria

***Corresponding Author:** Nadji Boughaba, Pediatric Surgery, Algeria.

Received: September 27, 2018; **Published:** October 24, 2018

Abstract

Rectal Prolapse is a known problem in children with anorectal malformations. We hereby present a particular case of total rectal prolapse following posterior sagittal anorectoplasty for Low-Type Anorectal Malformations in a girl, with a review of the literature.

Keywords: *Anorectal Malformation; Posterior Sagittal Anorectoplasty; Rectal Prolapse*

Introduction

Rectal prolapse is a recognized problem in patients with anorectal malformations [1-5]. Posterior sagittal anorectoplasty (PSARP) is an established technique to repair anorectal malformations [1-3] and may decrease the incidence of rectal prolapse when compared with other techniques [5]. The incidence of prolapse after PSARP is low [6]; however, no study has determined its exact incidence in a large series or defined the contributing factors that may predispose a patient to develop prolapse.

We hypothesized that postoperative rectal prolapse would be more likely in patients with complex anorectal anomalies, deficient muscles, those with spinal or sacral abnormalities, and those with severe constipation or diarrhea [2].

Case Report

This is the case of a female patient, currently 5 years of age, who has been followed in our department since her birth for a low-type anorectal malformation consisting of a vestibular fistula (Figure 1). Imaging investigations revealed associated left renal agenesis, right kidney hydronephrosis secondary to complex uropathy, and dolicho-megacolon with anteversion of the sigmoid loop (Figure 2).

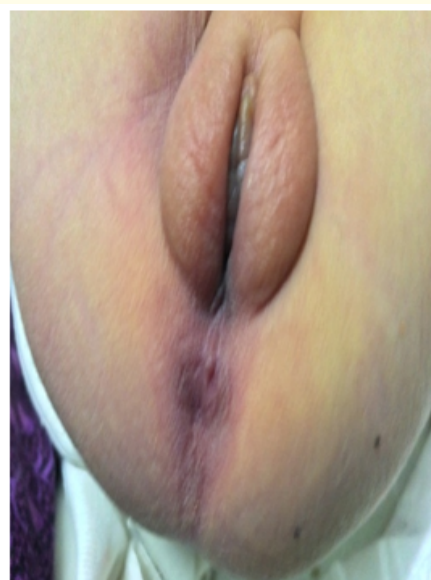

Figure 1

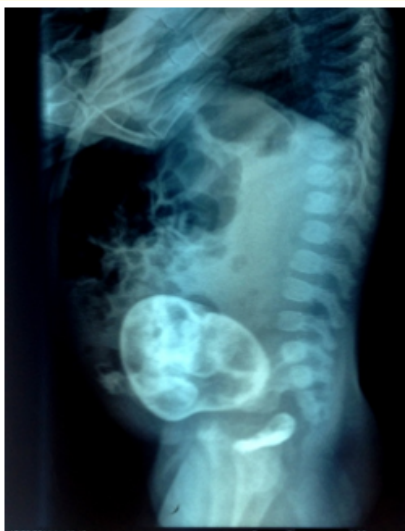

Figure 2

At the age of 4 months, the patient underwent a Limited Posterior Sagittal Anorectoplasty after a pre-operative localization of the site of the neo-anus was made by electrostimulation. The postoperative course was smooth, without stenosis or early rectal prolapse.

However, the patient was hospitalized on many occasions for febrile urinary tract infections and profuse diarrhea. Radiological investigation of the urinary tract revealed a right solitary kidney with a refluxing and obstructive right megaureter with a posterior crossing of its iliac component with the right external iliac artery (Figure 3).

At 14 months of age, the patient underwent an intra-vesical cross-trigonal ureteroneocystostomy combined with extra-vesical dissection and posterior uncrossing the right ureter of the right external iliac artery (Figure 3). The postoperative course was uneventful.

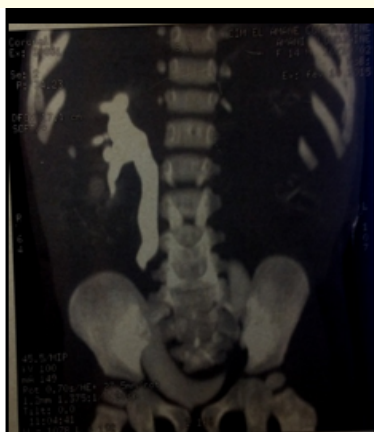

Figure 3A1: URO-CT scan.

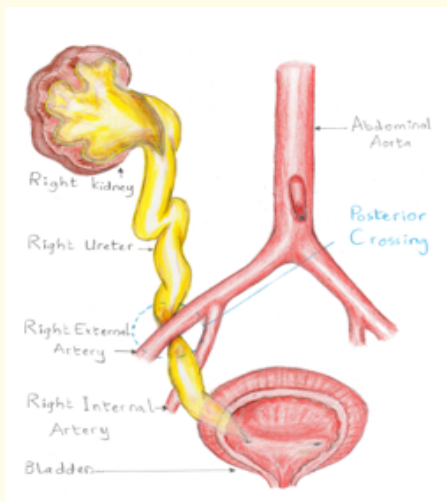


Figure 3A2: Intra-operative aspect.

Figure 3

The patient's chronic diarrhea motivated several hospital admissions, and she was noticed to progressively develop rectal prolapse one year after her anorectoplasty, initially responding to manual reductions in outpatient clinics, then becoming permanently protruded.

Therefore, the patient underwent three reduction attempts of her recto-colic prolapse under sedation, all of which failed. Examination revealed this was a total colonic wall circumferential prolapse affecting the sigmoid and the descending colon (Figure 4). During the same sedation, a verification of the good anal location and the good functionality of the external sphincter muscles by electrostimulation has been realized.

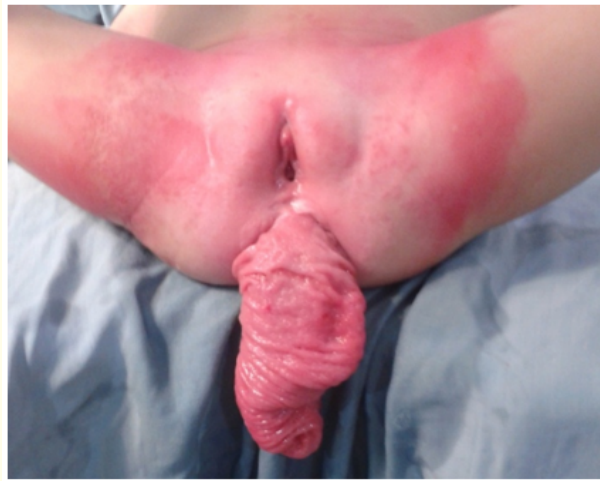

Figure 4: Total Recto-left colonic wall circumferential prolapse

A redo Posterior Sagittal Anorectoplasty was performed at the age of 2 years, but unfortunately failed to address the prolapse as it rapidly recurred.

At the age of 3 years, a posterior Rectopexy by the open procedure was performed via a Pfannenstiel's incision. The peritoneal reflection was divided and the rectum was mobilized anteriorly and posteriorly. Two interrupted non-absorbable sutures were placed between the posterior lateral aspect of the rectum and fascia over the sacral promontory on either side, and it was successfully achieved.

The patient is currently 5 years of age, with no rectal prolapse upon consecutive follow-up.

Discussion

Very few articles have been published addressing the topic of rectal prolapse after PSARP, and its true incidence has yet to be determined [1,3-5]. Currently, there is no consensus regarding the definition of rectal prolapse, which complicates the accurate evaluation of outcomes for both patients and surgeons [1-5]. The definition of rectal prolapse differs among surgeons and therefore, the range of its reported incidence varies widely [6]. The condition can be a slight mucosal protrusion to a large full-thickness prolapse. Belizon., *et al.* [10] were the first to define rectal prolapse as a protrusion of the rectal mucosa greater than 5 mm. Our patient had total circumferential rectal prolapse of more than 5 cm. Circumferential prolapse could be related to the presence of poor anatomical prognostic factors, while a semi-circumferential prolapse may be associated with a poor surgical technique. We defined significant rectal prolapse as greater than 5 mm of prolapse mucosa because it is associated with more significant clinical implications. These include mucous production, a tendency to erode and bleed, and potential interference with anal canal sensation impacting on fecal continence and the patient's quality of life.

The reported incidence of rectal prolapse post PSARP described in the literature varies from 3.8 to 38% [11,12]. However, only cases that required surgical correction were considered in most reports [1-5,11- 13]. The incidence of rectal prolapse seems to be higher in

males compared to females; however, this finding did not reach statistical significance. In the literature, the incidence of rectal prolapse has been related to the type of ARM with an incidence that varies from 1.2 % in the recto-vestibular fistula to 6.8 % in recto-bladder neck fistula [10]. This low incidence is likely because of the focus on 3 important parts of the repair. The first is the technical step of tacking the rectum to the muscle complex [4]. This concept of tacking the posterior rectum to the levator muscle complex has been described for the treatment of prolapse in patients with no anorectal malformations [7]. The second is tapering the dilated rectum. A dilated rectum may contribute to prolapse because the rectum is lax and stretches the perirectal supporting tissues [4]. Tapering of the rectum is thought to eliminate these problems [5,8]. The tapering is not the only factor, because even patients who were tapered developed prolapse. The third factor is the tension that is maintained while anchoring the rectum to the muscle complex and when placing the anoplasty sutures [4]. This allows for the anus to retract slightly after completion of the procedure and may serve to prevent prolapse. All these maneuvers depend on the pelvic musculature, which, if deficient will more likely allow for prolapse.

The average time to develop prolapse was relatively short, within 1 - 2 years [10]. If we check in the general pediatric population, the exact etiology of rectal prolapse in children is unknown [15]. Rectal prolapse in children is associated with many conditions, such as chronic constipation, diarrheal disease, ulcerative colitis, malnutrition, Hirschsprung's disease, Ehlers-Danlos syndrome, myelomeningocele, rectal polyps, parasitic and neoplastic diseases of the rectum and after surgical repair of anorectal anomalies [15,16]. Rectal prolapse is commonly associated in children with cystic fibrosis occurring in approximately 20 percent of cases usually between six months and three years of age and often preceding the diagnosis of cystic fibrosis [17]. In children with cystic fibrosis, the prolapse often is recurrent and is probably related to malnutrition, poor muscle tone, and passage of voluminous stools [18]. Some authors recommend a sweat test for all cases of rectal prolapse [16,17].

With the recent advances in laparoscopy, laparoscopic repairs of anorectal malformations have gained popularity [8,9]. It has yet to be determined if the incidence of postoperative prolapse is different in laparoscopically assisted anorectoplasty compared to the open PSARP when long-term results are assessed. One key difference is that during the laparoscopic technique the rectum is not sutured to the levator musculature [8]. The laparoscopic technique does include retracting the rectum cephalad and securing it to the presacral fascia [8,9]. It is unclear whether omitting the step of securing the rectum to the muscle complex and replacing it with the pelvic hitch is successful in the long term in avoiding postoperative prolapse.

Patients with prolapse complained of symptoms, in accordance to what observed by Zornoza, *et al* [12]. The incidence of prolapse-related symptoms such as bleeding, mucus production, and discomfort is significantly higher in patients with more severe degrees of rectal prolapse. This is logical because a prolapse persistently protruding from the rectum has a higher risk of traumatic contact with the underwear and therefore a higher risk of irritation, with mucus production and bleeding. Our patient had a huge and permanent total rectal prolapse, that was not reducible and sometimes needed to be reduced under sedation.

An adequate bowel management program, which has to be tailored for each child can improve a minor prolapse mostly caused by constipation. This emphasizes the need for a classification of rectal prolapse that allows monitoring clinical improvements but also stresses the importance of a dedicated colorectal center that knows how to medically approach children with prolapse before any surgical decision is made [19]. Our patient had a total, progressive, rectal prolapse, increased by diffuse diarrhea, so it wouldn't respond to any bowel management program. It is recommended that surgeons consider a surgical repair for rectal prolapse based on the severity of the symptoms and on the impact on the quality of life experienced by the patient. If a patient with an evident prolapse does not complain of symptoms that interfere with his daily activities or with his continence, it does not necessitate any surgical correction. But in case of total and permanent rectal prolapse post PSARP, a surgical revision is indicated, of course after a functional as well as an anatomical assessment.

Our patient underwent a minimal posterior sagittal approach, mobilization of excess rectum, and a redo-anoplasty under tension as described in literature [8-21]. but unfortunately failed to address the prolapse as it rapidly recurred and it was predictable because it is actually a particular anatomical entity, a permanent total prolapse and secondary to a dolicho-megacolon, aggravated by a profuse and

chronic diarrhea in the context of an atypical malformation.

If we consider prolapse as a separate entity and we are thinking about its management as a total rectal prolapse recurrent and invalidating in a child, a wide variety of operations have been described for rectal prolapse, which reflects the lack of satisfaction with any single technique and lack of complete understanding of the pathophysiology of this condition in children. The various operative procedures for the management of rectal prolapse can be broadly classified as abdominal [20-26] or perineal [20], according to the operative approach. Other less invasive surgical options include injection sclerotherapy [14-27] and encircling of the anus [14-23]. With such a wide variety of treatment options for rectal prolapse and a variable success rate, the optimum treatment of this condition in children is still debated. Minimally invasive approaches such as encircling of the anus (Thiersch method); Linear electrocoagulation of the rectal mucosa under general anesthesia and sclerotic injections seem reserved only for benign medical prolapse and they are known by a rate of complications and significant recurrences. The suspension of the rectum according to ORR-Loygue-Carbonnet [28] is practiced via Abdominal or laparoscopic approach (Figure 5), where the rectum is dissected then attached to the anterior L5-S1 vertebral ligament via

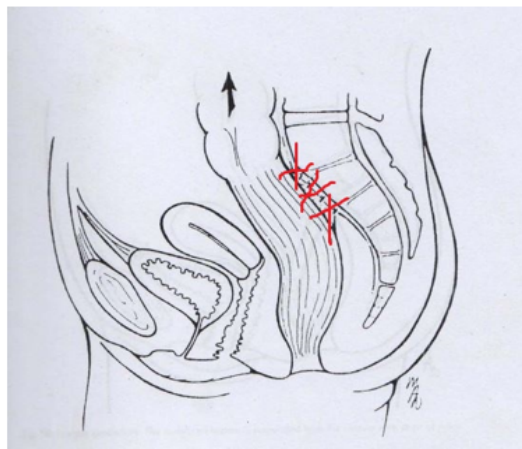


Figure 5

two lateral strips either prosthetic or aponeurotic (posterior Rectopexy), followed by closure of the peritoneum in the pelvis to recreate a pouch of Douglas, with a reported success rate ranging from 75 to 100% [20].

Conclusion

Rectal prolapse is a known complication that can occur after repair of anorectal malformations. The severity of associated congenital anomalies, the type of rectal malformation and the need for a colostomy in the neonatal period are risk factors significantly associated with the development of rectal prolapse.

It is necessary to classify rectal prolapse according to specific anatomic features that can be used to monitor clinical changes during the conservative treatment, to predict the need for surgical repair and to allow the comparison of outcomes among different centers.

Anorectal malformation can be part of a more complex syndrome that can hide other associated abnormalities. The occurrence of rectal prolapse post PSARP should prompt a search for other anatomical and metabolic abnormalities that may explain the occurrence of rectal prolapse, which will dictate the optimal medical management for the minor forms or surgical repair for complex and recurrent cases.

Bibliography

1. Pena A. "Posterior sagittal anorectoplasty: Results in the management of 322 cases of anorectal malformations". *Pediatric Surgery International* 3.2-3 (1988): 94-104.
2. Levitt Marc A., et al. "Anorectal Malformations". *Orphanet Journal of Rare Diseases* 2 (2007): 33.
3. Pena A. "Anorectal malformations". *Seminars in Pediatric Surgery* 4.1 (1995): 35-47.
4. Pena A. "Anorectal malformations". In: Ziegler M, Azizkhan R, Weber T, editors. *Operative Pediatric Surgery*. New York: Appleton and Lange (2003): 739-761.
5. Pearl RH., et al. "Posterior sagittal anorectoplasty for pediatric recurrent rectal prolapse". *Journal of Pediatric Surgery* 24.10 (1989): 1100-1102.
6. Caouette-Laberge L., et al. "Multiple-flap anoplasty in the treatment of rectal prolapse after pull-through operations for imperforate anus". *Journal of Pediatric Surgery* 22.1 (1987): 65-67.
7. Ripstein CB. "Massive rectal prolapse". In: Cooper P, editor. *The craft of surgery*. Boston: Little (1964): 1140-1145.
8. Georgeson KE., et al. "Laparoscopically assisted anorectal pull through for high imperforate anus-a new technique". *Journal Pediatric Surgery* 35.6 (2000): 927-931.
9. Albanese CT., et al. "One-stage correction of high imperforate anus in the male neonate". *Journal Pediatric Surgery* 34.5 (1999): 834-836.
10. Belizon A., et al. "Rectal prolapse following posterior sagittal anorectoplasty for anorectal malformations". *Journal Pediatric Surgery* 40.1 (2005): 192-201.
11. Sato H., et al. "The long-term prognosis of two-flap anoplasty for mucosal prolapse following anorectoplasty for anal atresia". *Pediatric Surgery International* 28.8 (2012): 841-846.
12. Zornoza M., et al. "Postoperative anal prolapse in patients with anorectal malformations: 16 years of experience". *Cirugía Pediátrica* 25.3 (2012): 140-144.
13. Pena A., et al. "Reoperations in anorectal malformations". *Journal Pediatric Surgery* 42.2 (2007): 318-325.
14. Fahmy MA., et al. "Outcome of submucosal injection of different sclerosing materials for rectal prolapse in children". *Pediatric Surgery International* 20.5 (2004): 353-356.
15. Siafakas C., et al. "Rectal prolapse in pediatrics". *Clinical Pediatrics* 38.2 (1999): 63-72.
16. Zempsky WT., et al. "The cause of rectal prolapse in children". *American Journal of Diseases Children* 142.3 (1988): 338-339.
17. Stern RC., et al. "Treatment and prognosis of rectal prolapse in cystic fibrosis". *Gastroenterology* 82.4 (1982): 707-710.
18. Rosentein BR. "Cystic fibrosis: other clinical manifestations". In: Taussig LM, Landau LI, eds. *Paediatric respiratory medicine*. St. Louis: Mosby (1999): 1033-1064.
19. Pena A., et al. "Bowel management for fecal incontinence in patients with anorectal malformations". *Journal Pediatric Surgery* 33.1 (1998): 133-137.

20. Sander S., *et al.* "Management of rectal prolapse in children Ekehorn's rectosacropexy". *Pediatric Surgery International* 15.2 (1999): 111-114.
21. Wyatt AP. "Perineal rectopexy for rectal prolapse". *British Journal Surgery* 68.10 (1981): 717-721.
22. Loygue J., *et al.* "Traitement chirurgical du prolapsus total du rectum par la rectopexiesuivant le procédé de Orr à propos de quatorze observations". *Mémoires Academie de Chirurgie* 83 (1957): 35-38.
23. Qvist N., *et al.* "Rectal prolapse in infancy: conservative versus operative treatment". *Journal Pediatric Surgery* 21.10 (1986): 887-888.
24. Abes M., *et al.* "Injection sclerotherapy of rectal prolapse in children with 15 percent saline solution". *European Journal Pediatric Surgery* 14.2 (2004): 100-102.
25. Abcarian H. "Prolapse and procidentia". In: Shackelford RT, Zuidema GD, eds. *Surgery of the alimentary tract*. 2nd edition. Philadelphia: Saunders (1991): 331-348.
26. Duthie GS., *et al.* "Abdominal rectopexy for rectal prolapse: a comparison of techniques". *British Journal of Surgery* 79.2 (1992): 107-113.
27. Wyllie GG., *et al.* "The injection treatment of rectal prolapse". *Journal Pediatric Surgery* 14.1 (1979): 62-64.
28. Oeconomopoulos CT., *et al.* "Thiersch's operation for rectal prolapse in infants and children". *American Journal of Surgery* 100 (1960): 457-461.

Volume 7 Issue 11 November 2018

©All rights reserved by Nadji Boughaba.